Tricks & Tips for Pedal/Tibial Access: Lessons from 6 years of routine tibiopedal access

Bob Tahara MD FACS FSVS RVT RPVI
Director,Allegheny Vein & Vascular,Bradford PA
Adjunct Assistant Professor of Surgery, Department of Surgery/Division Vascular Surgery, University of Pittsburgh School of Medicine

@OEIS 6th Annual Meeting, Tampa Bay, Fl
05-06 APR2019

ALLEGHENY VEIN & VASCULAR

Disclosures

- No commercial disclosures
- Not theoretical
- My routine, every case approach for the last 6+ years
- Femoral access is now rare in my practice (exactly n=1 for 2018)

ALLEGHENY
VEIN & VASCULAR

Overview

- Introduction
- Tips & Tricks
  - Setting yourself up for success
  - Imaging and preop pearls
  - Access tips & pearls
  - Device tips & tricks **slides included for reference**

ALLEGHENY VEIN & VASCULAR

Introduction

- “Always Cheat, Always Win” –circa 2000 - Clint Smith @Thunder Ranch TX
- Keys to maximizing success of performing intervention via tibiopedal access
  - Mindset
  - Imaging
  - Technique
  - Tools

ALLEGHENY VEIN & VASCULAR

Tibiopedal Access options

- Single tibial/pedal access with ALL treatment from that access
- Dual tibial/pedal (or more) access with all treatment via one or both tibial accesses
- **D**eliberate **A**ccess of **O**ccluded **T**ibial/pedal **A**rteries (DAKOTA) either single or dual
- ~~Tibial/pedal access + concomitant CFA/SFA (whether antegrade or retrograde)/SAFARI type~~

ALLEGHENY VEIN & VASCULAR

Setting up for Success-Preop Optimization

- There is a learning curve so mindset is paramount
- You have to program in **patience**
- Absolute necessity is adequate preop imaging/mapping
  - Duplex - requires staff expertise but least risk, no contrast and most accurate
  - CTA/MRA: None ordered infrainguinal in 9+ years
  - ~~Formal antecedent angiography from above~~

ALLEGHENY VEIN & VASCULAR

Lower Extremity Arterial

Last Name [redacted]
First Name [redacted]
DOB 4/20/43

Date of Angio 2/20/19
AVV# 107070
Date of DX U/S 1/22/19

R CFA access
depth 1.47
diam 0.80
plaque Y / N

L CFA access
depth
diam
plaque Y / N

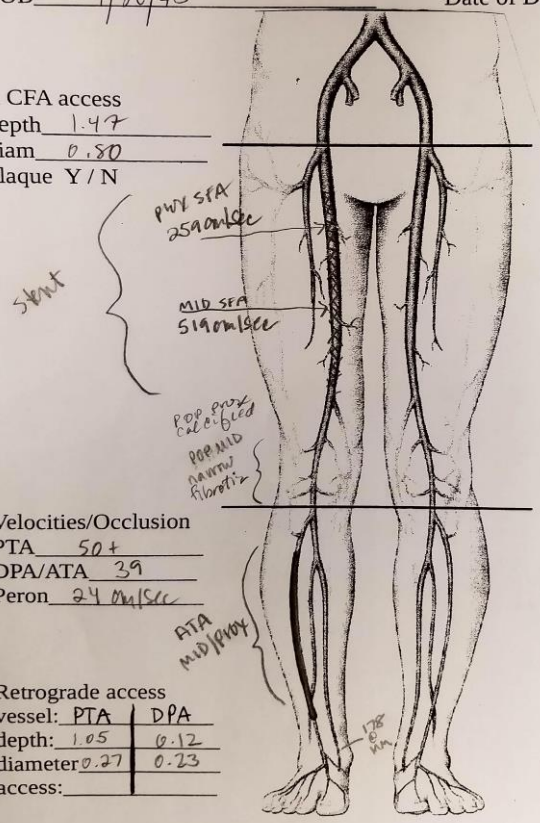

Velocities/Occlusion
PTA 50+
DPA/ATA 39
Peron 24 cm/sec

Velocities/Occlusion
PTA
DPA/ATA
Peron

Retrograde access

vessel:	PTA	DPA
depth:	1.05	0.12
diameter	0.27	0.23
access:		

Retrograde access

vessel:	PTA	DPA
depth:		
diameter:		
access:		

Lower Extremity Arterial

Last Name [redacted]
First Name [redacted]
DOB 12/5/35

Date of Angio 2/7/19
AVV# 117772
Date of DX U/S 2/5/19

R CFA access
depth
diam
plaque Y / N

L CFA access
depth 2.36
diam 0.64
plaque (Y) / N

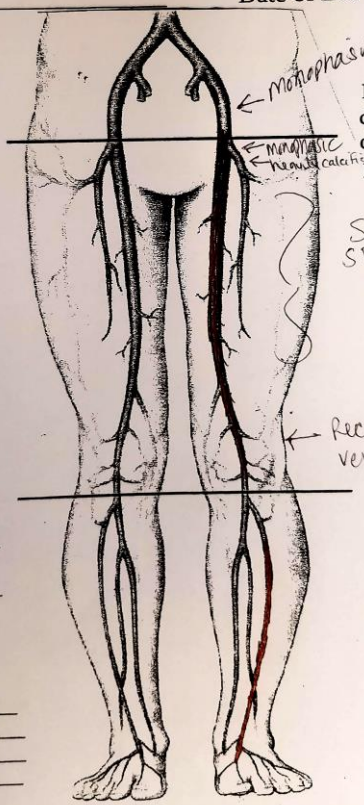

Velocities/Occlusion
PTA
DPA/ATA
Peron

Velocities/Occlusion
PTA 21cm/s
DPA/ATA occluded
Peron 15cm/s

Retrograde access

vessel:	PTA	DPA
depth:		
diameter		
access:		

Retrograde access

vessel:	PTA	DPA
depth:	0.47cm	0.59cm
diameter:	0.23cm	0.24cm
access:	#2	#1

ALLEGHENY
VEIN & VASCULAR

Setting up for Success-Preop Optimization

- Room setup/patient positioning
  - I do all tibiopedal access from patient's right side (I am RH dominant). Experiment to see if L side is better if you are LH dominant- it may or may not work
  - Patient should be all the way to the end of the bed- position bottom of foot 3-5cm from edge.
  - Use stacked towels to position foot- more vertically for DPA, towels under knee to externally rotate knee for PTA access

ALLEGHENY VEIN & VASCULAR

Imaging Pearls

- 11/12/15 MHz probes- you need definition not depth
- Linear probe actually better than hockey stick
- All presets suck- you will need to work with your techs to tweak
- Avoid over-gaining and ANYTHING that increase perceptible temporal lag- the delay will kill your chances of reliable access

ALLEGHENY
VEIN & VASCULAR

Imaging Pearls

- Ultrasound guidance essential for access of patent tibiopedal vessels- operator performed is preferred but is absolutely required for success when attempting DAKOTA type access
- Long term success mandates operator performed ultrasound guidance with the nondominant hand (in my case the left hand)
- The RVT is in the room to help optimize your image with ”knob twiddling”-image optimization!

ALLEGHENY
VEIN & VASCULAR

Imaging Pearls

- We use GE S7's exclusively- great image quality but some issues with the units (keyboard design defect)
- GE probes handle better and are lighter and more ergonomic than any other manufacturer (hint, hint as well as challenge to the other big players)
- GE can be like dealing with the DMV!

ALLEGHENY
VEIN & VASCULAR

Access Tips & Pearls

- Use pedal specific 4Fr micropuncture access kits
- No need for “enhanced needles”- marketing BS
- Micro-wires are all floppy and have a tendency to jam in the needle hub so be aware as this can push the needle tip subintimal or even out

ALLEGHENY
VEIN & VASCULAR

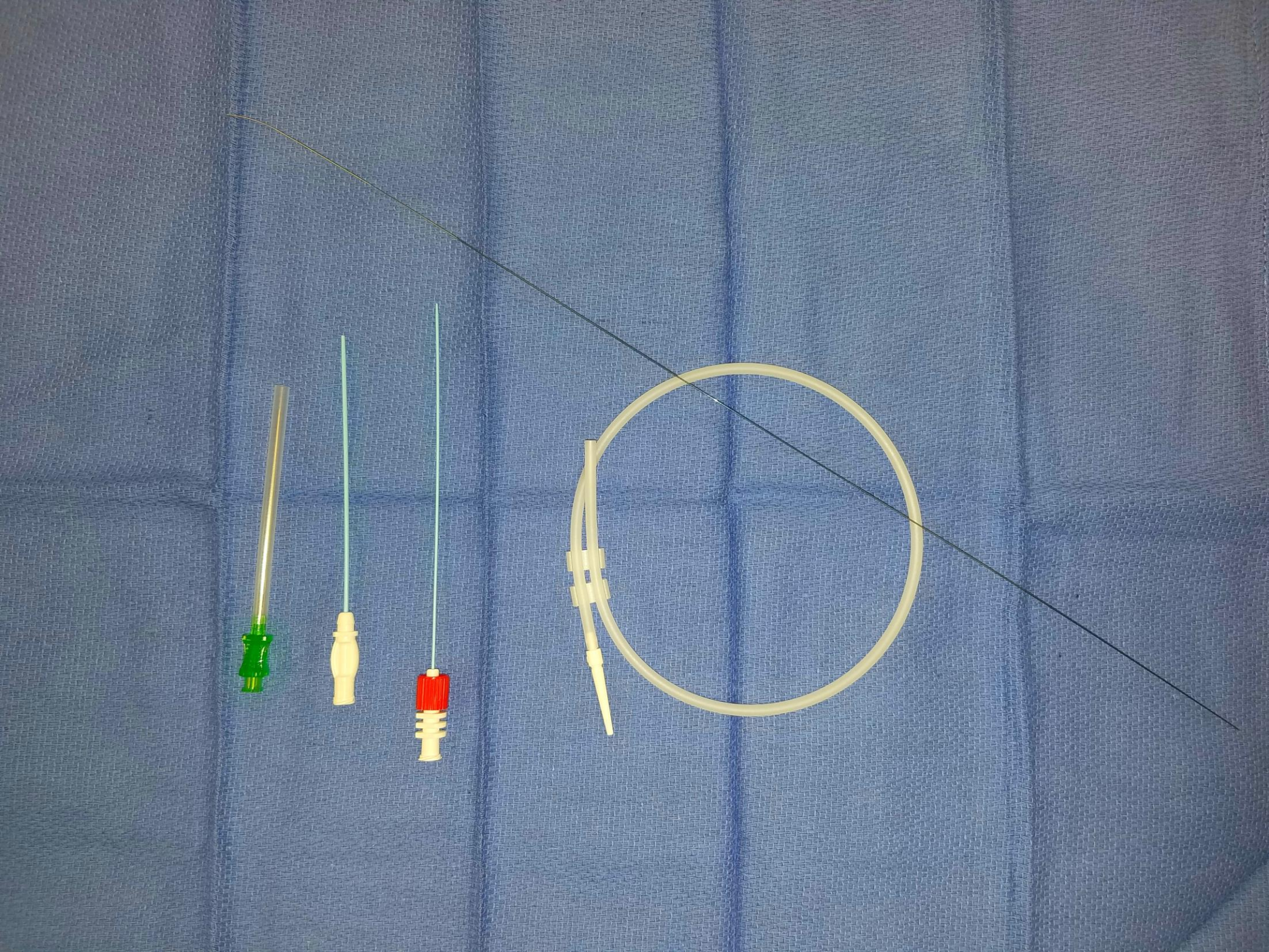



Access Tips & Pearls

- Difficult or occluded vessels may require multiple wires to get enough purchase to pass a sheath
- May require floppy, hydrophillic or even CTO type wires (micropuncture wire, V18, Asahi 20 and 30 weight CTO wires)
- PEARL: keep the floppy microwire moving as you advance it to prevent hangup and dissection. Rotate as you advance –but- only after you have the wiretip visualized at the opening of the bevel

ALLEGHENY
VEIN & VASCULAR

Access Tips & Pearls

- We pass the naked micro dilator OTW alone to predilate before passing the dilator/sheath assembled. Prevents wire kinking and laceration particularly in heavily calcified and diabetic pts
- Once micro sheath is in then upsize to 035 wire preferentially or 018 to get standard 4Fr sheath in place. Upsize only after getting secure access with standard 4Fr sheath placement
- Metric “access time” to be from initial stick to placement of our final working sheath. Track this time for yourself!

ALLEGHENY
VEIN & VASCULAR

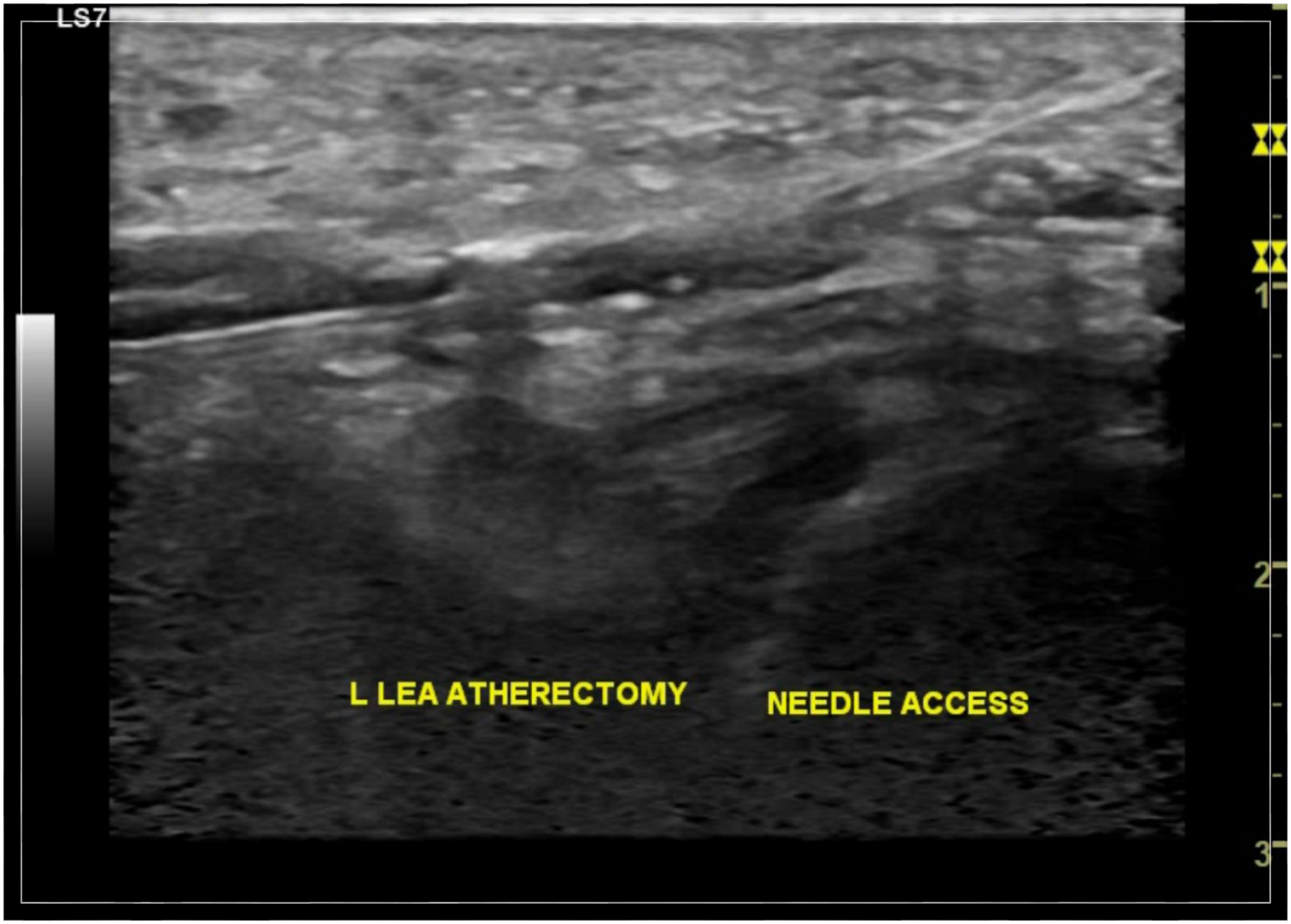

ALLEGHENY
VEIN & VASCULAR

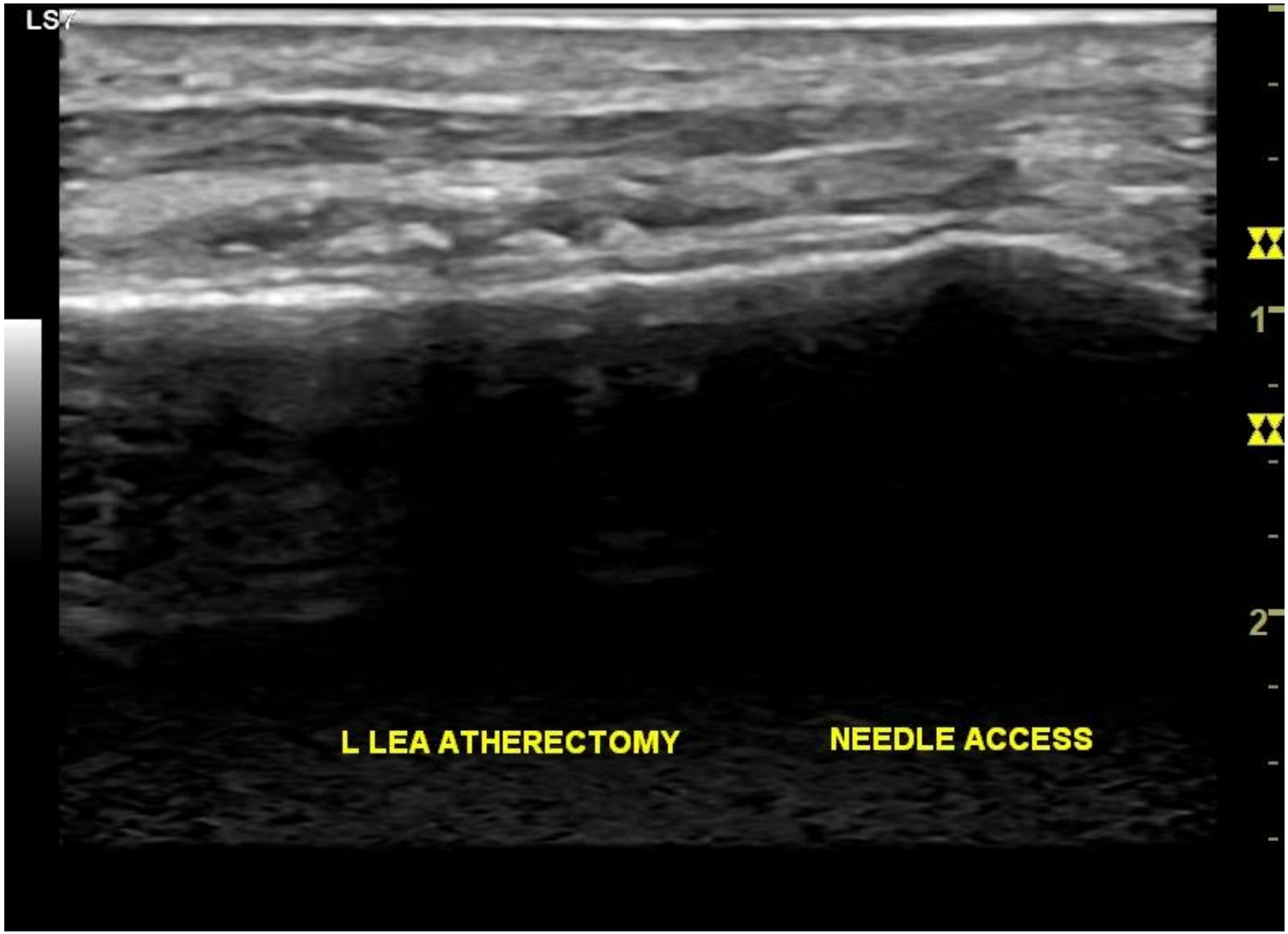

ALLEGHENY
VEIN & VASCULAR

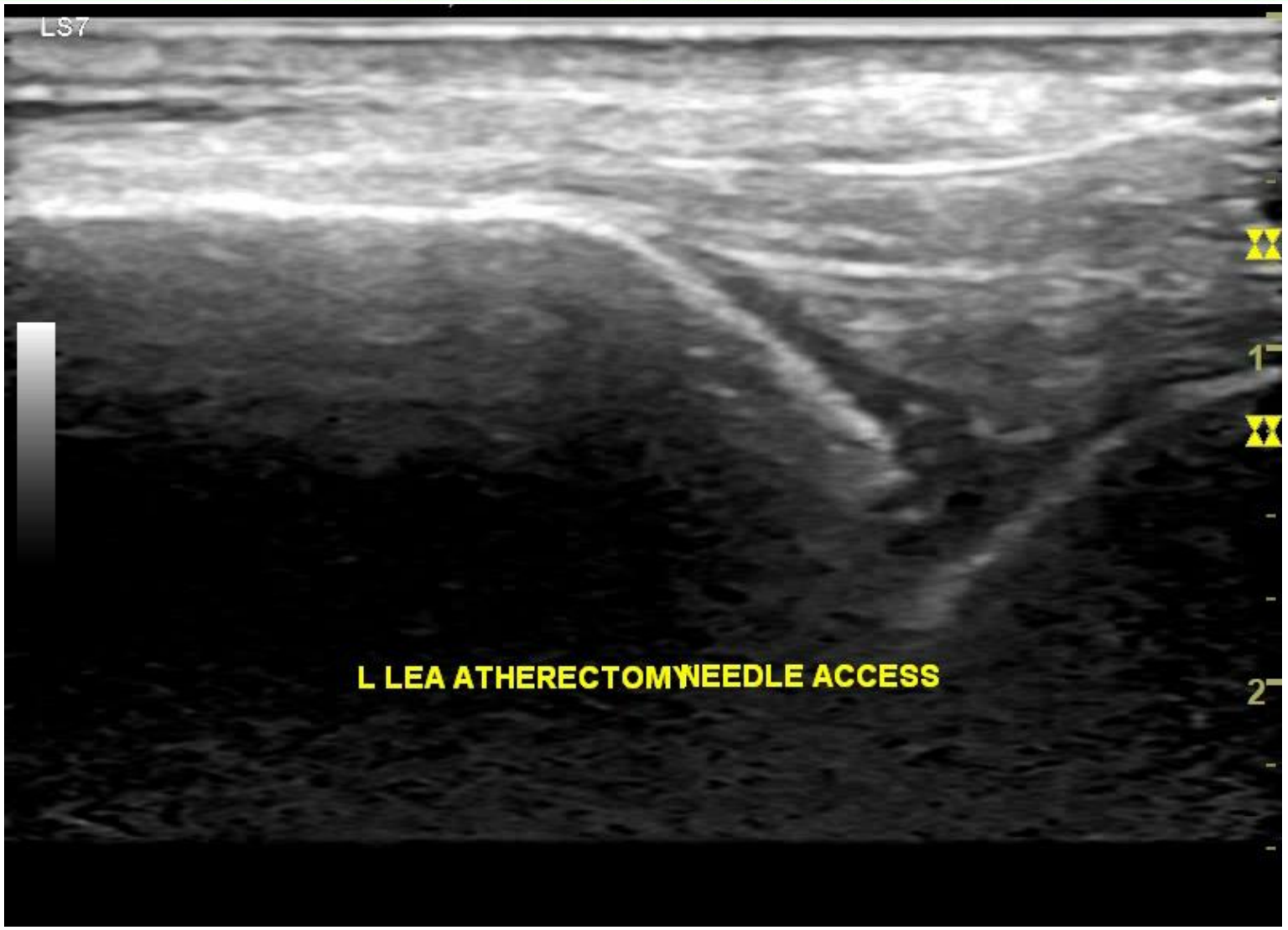

ALLEGHENY
VEIN & VASCULAR

ALLEGHENY
VEIN & VASCULAR

Trans-tibial Pearls

- V18 wire with tip bent into 2 tandem 30* angles
- Will select >80% of transtibial
- J curve or U curve 4Fr catheters for really acute takeoffs
- Cut or modified 4Fr Contra works well but beware drag on the wire when swapping out
- 018 crossing cath whether using 018 or 014 wires

ALLEGHENY
VEIN & VASCULAR

Advanced Device Options

- Essentially anything that is not a 4Fr or potentially 5Fr device used via said sheath
- Most useful option for bigger devices or 035 system devices is to go “bareback”
- Bareback devices
  - 4Fr sheath OD=6Fr device OD
  - 5Fr sheath OD = 7Fr device OD

ALLEGHENY
VEIN & VASCULAR

Advanced Device Options

- Pearl for Bareback devices: use either 035 or 018 stiff wire systems. 014 are troublesome for replacing the sheath after devices have been used
- Usual Drill:
  - Place 035/018 wire
  - Pull sheath
  - Load bareback device on wire while digitally controlling the access site
  - Pass device and do that voodoo you do
  - Remove device and replace 4 or 5Fr sheath over wire

ALLEGHENY
VEIN & VASCULAR

Advanced Device Options

- But what are realistic limits of sheath/device size?

ALLEGHENY
VEIN & VASCULAR

Advanced Device Options

- But what are realistic limits of sheath/device size?
  - 4Fr sheath (6Fr OD) = 2mm
  - 5Fr sheath (7Fr OD) = 2.33 mm
  - 6Fr sheath (8Fr OD) = 2.67mm
  - 7Fr sheath (9Fr OD) = 3mm
- Tendency to underestimate tibial sizes
- *Measure your next 10 cases* with duplex and see what average size is
- DEFINITELY be >2mm and darn near 3mm!

ALLEGHENY VEIN & VASCULAR

Advanced Device Options

- Entirely feasible to use a 7Fr system in a tibial (3mm diameter OD) –but-
- Increase both trauma and access site potential problems
- Vessel prep before attempting to pass is key: this may require atherectomy and WILL require PTA with minimally a 3mm balloon
- Intra-arterial NTG infusion may be needed if severe spasm noted

ALLEGHENY
VEIN & VASCULAR

Advanced Device Options

- Entirely feasible to use a 7Fr system in a tibial (3mm diameter OD) –but-
- Avoid pushing size if heavily calcific or even marginal size
- Routine use of 4Fr sheath (6Fr,~2mm OD) = zero site complications over past 6+ years

ALLEGHENY
VEIN & VASCULAR

Advanced Device Options

- Can use with either upsized sheath or bareback technique including
  - “normal” profile (6Fr, 7Fr) nitinol or BEX stents
  - Covered stent graft (Viabahn) or iCast

ALLEGHENY
VEIN & VASCULAR

Pearls for Viabahn

- Stick with the 018 device if possible (7Fr, 2.33mm OD). Predilate with 5Fr sheath sytem
- It will not go in smoothly- you will feel the "washboard" as it enters the vessel
- Need to gently advance it so no tearing of arteriotomy and no release of the graft as it enters
- Vessel prep before attempting to pass is key: this may require atherectomy and **WILL** require PTA with minimally a long 3mm balloon

ALLEGHENY VEIN & VASCULAR

Summary

- Mindset and patience is paramount when beginning to use routine pedal access
- Proper preop mapping is mandatory for success
- Imaging needs optimized beyond factory presets
- Use pedal specific access kits but be prepared to use added wires as needed
- Drive your own ultrasound with your nondominant hand
- Grab me at break for any and all questions you may have- there aren’t any secrets here!

ALLEGHENY
VEIN & VASCULAR

Questions? Comments?

Feel free to call, email, or send carrier pigeon

Bob Tahara MD FACS FSVS RVT RPVI

Director

Allegheny Vein & Vascular

Bradford PA

(814) 368-8490

kodb2105@icloud.com

ALLEGHENY VEIN & VASCULAR